

Treatment Approaches for Oroantral Fistula: Two Case Studies

Author details

Corresponding Author

Dr. Ankita Raj¹: Professor, Department of Oral and Maxillofacial Surgery, Rama Dental College Hospital and Research Centre, Kanpur, Uttar Pradesh, India

drankitaraj.rdc@ramauniversity.ac.in

8887577724

Dr. Akash Tiwari²: post graduate student, Department of Oral and Maxillofacial Surgery, Rama Dental College and Research Centre, Kanpur

akash.tiwari5186@gmail.com

9696643192

Dr. Ankur Rathaur³: senior lecturer, Department of Oral and Maxillofacial Surgery, Rama Dental College, Hospital and Research Center, Kanpur, Uttar Pradesh, India

ankurrathaur10@gmail.com

8802879982

ABSTRACT

Oroantral communication refers to an abnormal opening between the oral cavity and the maxillary sinus¹. When this opening does not close on its own, it can persist and become lined with epithelium, resulting in the formation of an oroantral fistula². This condition is frequently seen after extraction of maxillary premolars and molars due to the close anatomical relationship between their root apices and the maxillary sinus³. The clinical presentation of an oroantral fistula can range from passage of fluids between the mouth and nose to pain, discharge of pus, changes in voice, and even involvement of multiple sinuses⁴. Various surgical techniques are available for its treatment, among which the buccal fat pad method is considered both reliable and effective⁵. This article presents two successful cases of oroantral fistula that were treated using the buccal fat pad approach.

1. Introduction

Oroantral communication (OAC) is defined as an abnormal opening between the oral cavity and the maxillary sinus¹. If this opening does not heal spontaneously, it may persist and become lined by epithelium, eventually leading to the formation of an oroantral fistula (OAF)². This epithelial lining typically develops when the defect remains open for more than 48–72 hours⁶.

Such complications most commonly arise during the extraction of maxillary premolars and molars, accounting for nearly half of reported cases³. This is primarily due to the close anatomical relationship between the roots of these teeth and the maxillary sinus⁷. Other contributing factors include fracture of the maxillary tuberosity, periapical or dentoalveolar infections involving posterior teeth, displacement of dental implants into the sinus, traumatic injuries, and the presence of cysts or tumours in the maxilla⁸. Additional

causes may include osteoradionecrosis, breakdown of surgical flaps, wound dehiscence after implant failure, and complications associated with procedures such as the Caldwell–Luc operation⁸. These conditions may predispose the maxillary sinus to pathological changes, thereby interfering with proper healing⁴.

A variety of surgical methods have been described for the closure of oroantral communications⁹. These include the use of buccal and palatal flap techniques and their modifications, as well as the application of alloplastic materials such as gold foil, gold plates, soft polymethylmethacrylate, and lyophilized collagen⁹. Autogenous bone grafts have also been utilized¹⁰. The selection of an appropriate technique depends on several factors, including the size, location, and duration of the defect, as well as the clinician's expertise⁵.

Among the available options, the pedicled buccal fat pad flap is considered a straightforward and dependable method for managing such defects⁵.

In this report, we describe two cases of oroantral fistula that were successfully

treated using the buccal fat pad technique⁵.

2. Patient and observation

A 60-year-old patient was referred to the oral and maxillofacial surgery department by a general dentist with complaints of air passage and purulent discharge into the oral cavity. The patient had a history of well-controlled diabetes and reported undergoing a tooth extraction approximately eight months earlier. Extraoral examination revealed no significant findings. Intraoral assessment showed poor oral hygiene and missing teeth numbered 16, 26, 35, 46, and 47. The mucosa surrounding the region of tooth 26 appeared normal; however, a fistulous tract was identified using a gutta-percha cone.

Panoramic radiography demonstrated a bony defect establishing a communication between the oral cavity and the left maxillary sinus (Fig. 1). A CT scan further confirmed the presence of this defect and revealed mild thickening of the sinus mucosa.

Based on these findings, the patient was prescribed antibiotics (amoxicillin with clavulanic acid for 10 days) along with a nasal decongestant to manage

the associated sinusitis. Surgical closure of the oroantral fistula using the buccal fat pad (BFP) technique was planned.

The procedure was carried out under local anaesthesia. An intrasulcular incision extending from tooth 28 to 25, with a mesial releasing incision, was made to elevate a mucoperiosteal flap and expose the defect. Careful debridement of the area was performed, including removal of the fistulous tract. The maxillary sinus was then irrigated with saline solution to ensure proper cleansing.

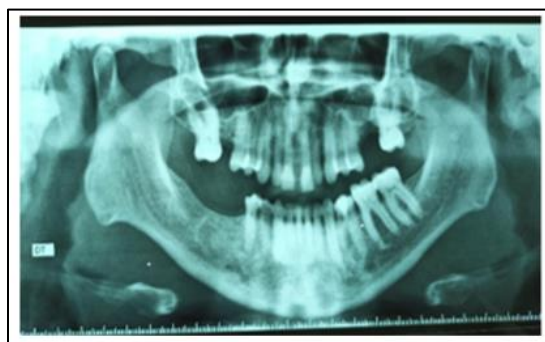


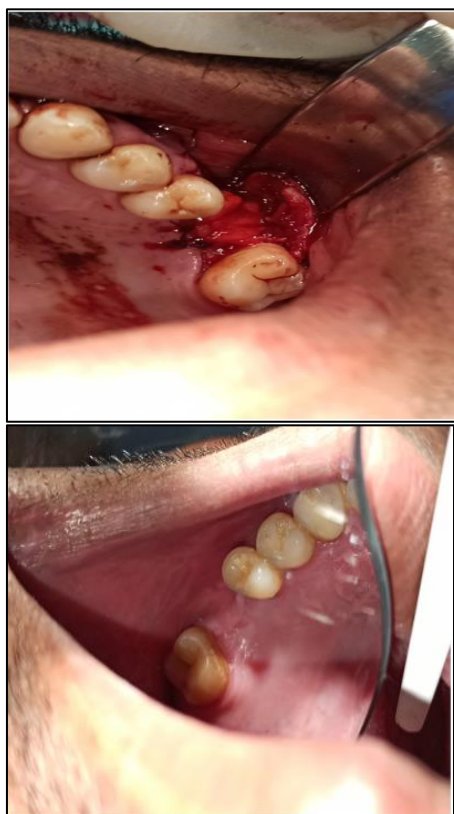Fig 1

A horizontal incision was made at the periosteal level opposite tooth 28 to access the buccal fat pad. The fat pad was carefully mobilized, advanced into the alveolar defect, and secured over the bony opening (Fig. 2). The mucoperiosteal flap was then

repositioned and sutured tightly to completely cover the buccal fat pad.

Postoperatively, the patient was maintained on antibiotics for 10 days, along with prednisolone at a dose of 60 mg per day for 5 days, as well as paracetamol and a nasal decongestant.

At the 10-day follow-up, healing was satisfactory with successful closure of the oroantral fistula. A six-month review demonstrated complete healing and restoration of normal function.



Fig

Fig 3

2

Case 2

A 45-year-old patient presented with delayed healing and passage of air from the extraction site of the left maxillary first molar, which had been removed one month earlier.

Intraoral examination revealed an unhealed socket at the extraction site (Fig. 4). Panoramic radiography demonstrated a small bony defect creating a communication between the oral cavity and the maxillary sinus. A CT scan further showed thickening of the sinus mucosa, reduced aeration of the nasal meatus, and opacification of the ethmoidal air cells (Fig. 5).

For management, the patient was prescribed amoxicillin combined with clavulanic acid for 10 days. Surgical closure of the oroantral communication using the buccal fat pad (BFP) technique under local anesthesia was planned shortly thereafter. Following elevation of a mucoperiosteal flap, a significant bony defect was identified. The fistulous tract was excised, and the sinus was irrigated with saline solution. The defect was then closed using the buccal fat pad, which was carefully positioned over the site and secured with tight sutures (Fig. 6), followed by repositioning of the flap.

Follow-up evaluations at 10 days and 6 months showed satisfactory healing without any complications.

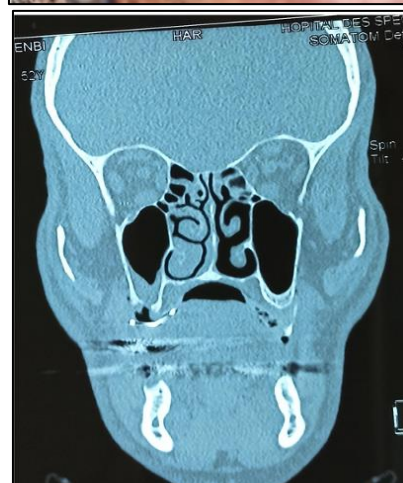
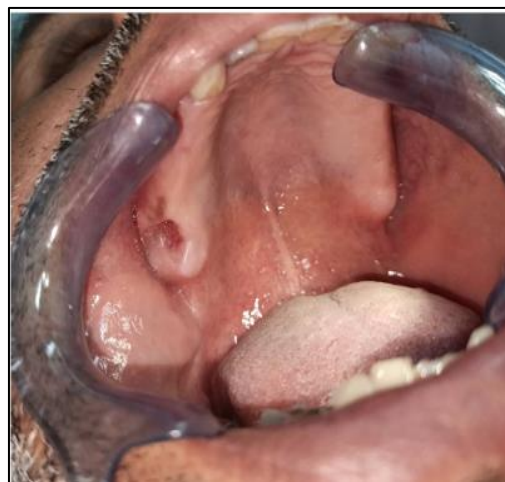
Fig 4

Fig 5

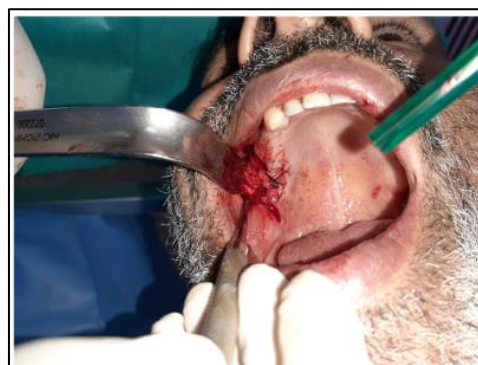

Fig 6

3. Discussion

Oroantral communications (OACs), defined as abnormal openings between the oral cavity and the maxillary sinus, are frequently encountered in dental practice, particularly following extraction of posterior maxillary teeth³. Reported incidence rates may reach up to 11%³. The removal of the palatal root of the maxillary first molar is often implicated due to its close anatomical relationship with the sinus, as observed in our cases.

When an oroantral fistula (OAF) is suspected, comprehensive clinical and radiographic evaluation is essential¹¹. These defects can serve as a route for microbial invasion, including bacteria and fungi, potentially leading to maxillary sinusitis or even pansinusitis⁴. Clinical manifestations may present in either acute or chronic forms⁴. Acute symptoms can include nosebleeds, passage of fluids or air between the oral cavity and nose, pain, and changes in voice. Chronic presentations may involve persistent pain, fluid leakage, antral polyp formation, postnasal discharge, altered taste sensation, voice changes, ear discomfort, and mucopurulent nasal discharge, as seen in our patients.

Radiographic assessment plays a key role in diagnosis¹². Panoramic imaging can reveal defects in the alveolar bone, while Waters' view may help identify sinus involvement¹². Advanced imaging modalities such as cone beam computed tomography (CBCT) or conventional CT scans provide detailed visualization of the communication¹², as well as associated findings like mucosal thickening, sinus opacification, reduced aeration of the nasal passages, and involvement of adjacent sinuses such as the ethmoidal air cells.

Timely closure of an OAF is critical to prevent the entry of food particles and saliva into the sinus, which can result in infection, delayed healing, and chronic sinus disease⁹. However, it is important to first control any existing infection before attempting surgical repair⁹. In patients with sinusitis, a course of antibiotics such as amoxicillin with clavulanic acid (1 g/125 mg, three times daily for 10–14 days), along with nasal decongestants and nonsteroidal anti-inflammatory drugs, is commonly prescribed⁴. Sinus irrigation may also support treatment⁴. In cases of chronic sinus disease unresponsive to medical therapy, surgical approaches such as endoscopic

sinus surgery or the Caldwell–Luc procedure may be required⁸.

The choice of technique for OAF closure depends on factors such as the size and duration of the defect, as well as considerations for postoperative rehabilitation. Small communications less than 2 mm in diameter often heal spontaneously¹³, whereas larger defects exceeding 3–4 mm typically persist and require surgical intervention¹³.

Various surgical methods have been described, including buccal advancement flaps, palatal flaps, rotational and hinged flaps, island flaps, and the use of the buccal fat pad (BFP)⁹. In our cases, the BFP technique was selected due to the relatively large size (greater than 5 mm) and chronic nature of the defects.

The buccal fat pad has been widely utilized for closure of oroantral defects, either alone, combined with skin grafts, or covered with biomaterials. Its anatomical features were first described in the 18th century, and its clinical application as a pedicled graft was later introduced. The BFP consists of a central body with four extensions: buccal, pterygoid, superficial temporal, and deep temporal. The buccal extension lies superficially within the

cheek, while the others are situated more deeply.

Surgically, the procedure involves creating a circular incision around the fistula with adequate margins, followed by removal of the epithelial tract and inflamed tissue. Releasing incisions are then made to elevate a trapezoidal mucoperiosteal flap. The buccal fat pad is accessed through a small incision in the periosteum posterior to the zygomatic buttress, gently mobilized, and advanced into the defect. It is sutured without tension, and the flap is repositioned to partially or completely cover the fat pad. The exposed portion undergoes epithelialization within 2 to 4 weeks¹⁴, during which granulation tissue forms and is gradually replaced by stratified squamous epithelium.

Long-term follow-up, ideally up to one year, is recommended to ensure successful healing⁶ and to detect any recurrence. In our cases, complete healing was observed after more than six months.

The buccal fat pad technique offers several advantages, including a high success rate, ease of execution, suitability under local anesthesia, minimal donor site morbidity⁵, reduced

risk of infection, and preservation of vestibular depth. However, it does have some limitations, such as its one-time use, potential for postoperative trismus, limited applicability in very small or very large defects, and lack of rigid structural support⁵.

4. Conclusion

Oroantral fistulas are relatively common complications encountered in dental practice. Accurate diagnosis depends on thorough clinical assessment supported by appropriate radiographic investigations. Prompt closure of postoperative oroantral communications is essential to prevent the development of fistulas and associated sinus complications. The buccal fat pad technique is a dependable, simple, and predictable method for managing and closing oroantral fistulas.

REFERENCES

1. Killey HC, Kay LW. Possible sequelae when teeth are extracted from the upper jaw. *Br Dent J*. 1967;122:7–14.
2. Punwutikorn J, Waikakul A, Pairuchvej V. Clinically significant oroantral communications. *Int J Oral Maxillofac Surg*. 1994;23:19–21.
3. Peterson LJ, Ellis E, Hupp JR, Tucker MR. *Contemporary Oral and Maxillofacial Surgery*. 6th ed. Mosby; 2014.
4. Brook I. Sinusitis of odontogenic origin. *Otolaryngol Head Neck Surg*. 2006;135:349–355.
5. Egyedi P. Utilization of the buccal fat pad. *J Maxillofac Surg*. 1977;5:241–244.
6. Visscher SH, van Minnen B, Bos RR. Closure of oroantral communications. *J Oral Maxillofac Surg*. 2010;68:1384–1391.
7. Waite PD, Bernier WE. Anatomic considerations of maxillary sinus. *J Oral Surg*. 1980;38:52–55.
8. Hanazawa Y, Itoh K, Mabashi T, Sato K. Closure using buccal fat pad graft. *J Oral Maxillofac Surg*. 1995;53:771–775.
9. Abuabara A. Management of oroantral fistula. *J Can Dent Assoc*. 2006;72:455–459.
10. Haas R et al. Bone grafts for oroantral fistula closure. *Int J Oral Maxillofac Surg*. 2003;32:607–611.
11. Borgonovo AE et al. Surgical options in oroantral fistula

- treatment. *Open Dent J.* 2012;6:94–98.
12. Scarfe WC, Farman AG. Cone-beam CT in dentistry. *Dent Clin North Am.* 2008;52:707–730.
13. Rehrmann A. Closure of oroantral communications. *DtschZahnarztl Z.* 1936;39:1136–1139.
14. Tideman H et al. Buccal fat pad as pedicled graft. *J Oral Maxillofac Surg.* 1986;44:435–440.