

Pleomorphic Adenoma of Hard Palate: A Case Report and Review of Literature

Shivendra Kumar Singh¹, Waseem Khan², Nishant Singh³, Mayank Verma⁴

¹ Reader, Department of oral and maxillofacial surgery, Rama Dental College, Kanpur

² Post graduate 3rd Year, Department of oral and maxillofacial surgery, Rama Dental College, Kanpur

³ Professor, Department of oral and maxillofacial surgery, Rama Dental College, Kanpur

⁴ Postgraduate 3rd Year, Department of oral and maxillofacial surgery, Rama Dental College, Kanpur

Abstract

Pleomorphic adenoma (PA) also known as “mixed salivary gland tumor” accounts for 60 – 70% benign tumor of salivary gland, on histopathologically point of view PA carry vast majority of diversity on both major and minor salivary gland, PA of hard palate accounts for highest probability of occurrence (accounts for 13.1% - 51.4%) for minor salivary gland, apart from hard palate other sites involved Buccal mucosa (10%), upper lip (5.5%), retromolar area (0.7%) and floor of mouth.

The main objective of this case report is to present histopathological and surgical modality for treatment of PA of minor gland, this case report follow a patient, female of 46 years of age have swelling on palate since 2 years, asymptomatic to patient (e.g numbness, dysphagia, stridor and masticatory difficulty).

Introduction

Pleomorphic adenoma (PA) is the most common tumor (60%) of major and minor salivary glands, approximately 70% of the tumors of minor salivary glands are PAs, the most prevalent intraoral site is the palate, followed by upper lip, buccal mucosa, 13.9–51.4% of all salivary gland tumors arise from an intraoral site and 34.7–67.1% of them are benign in nature [1]. PA holds for vast different in histopathological as well as clinical features. With several differential diagnoses, the atypical presentations of this tumor are not unconventional, changes of conversion to malignant form holds for more than 50%, as its benign form its holds to grow as an increased mass with no pain associated unless it's been secondarily infected¹, Fine needle aspiration cytology (FNAC) as well as incisional biopsy (core biopsy) with radiographic intervention by CT (computed tomography) to check for bony erosion is the key important diagnostic criteria.

Case Report

A 46 year old female patient reported to our department, department of oral and maxillofacial surgery, with a chief complaint of swelling present on palate since 2 year, history reveals the swelling arise only since 2 years, tumor is slow growing, painless, oval and well circumscribed with adherence to hard palate mucosa, lesion is slight erythematous with size approximately 2 x 2 cm, extension of swelling from mid palate towards right side, underlying mucosa is

stretched and shiny compared to neighboring normal palatal mucosa, the checkup orthopantomogram (OPG) doesn't reveal any pathological symptoms, for definitive histopathological examination an incisional biopsy (biopsy tissue of size 0.9cm x 0.8cm from core part of lesion) taken and send for reporting which reveals pleomorphic adenoma of minor salivary gland.

After the histopathological examination, a definitive radiological examination was done CT (Computed Tomography) to reveal the extension of lesion and breach in palatal bone.

On the basis of pre surgical examination, the treatment protocol was “wide excision” of lesion followed by palatal obturator placement to hide the wide soft tissue defect.

On taking personal history, patient had history of tobacco chewing since 5 years.

The surgical procedure were performed under anesthesia, wide dissection was performed and the whole encapsulated tumor mass was excised along with the mucoperiosteum, Hemostas is achieved by use of electro surgery, As there is bony erosion present in the palatal bone. The gross wide excised lesion was sent for confirmatory diagnosis and confirmed of pleomorphic adenoma. The patient's postoperative course was uneventful. A palatal obturator was made in order to cover the soft tissue defect with COE PACK dressing beneath the obturator to avoid any irritation to the bone.

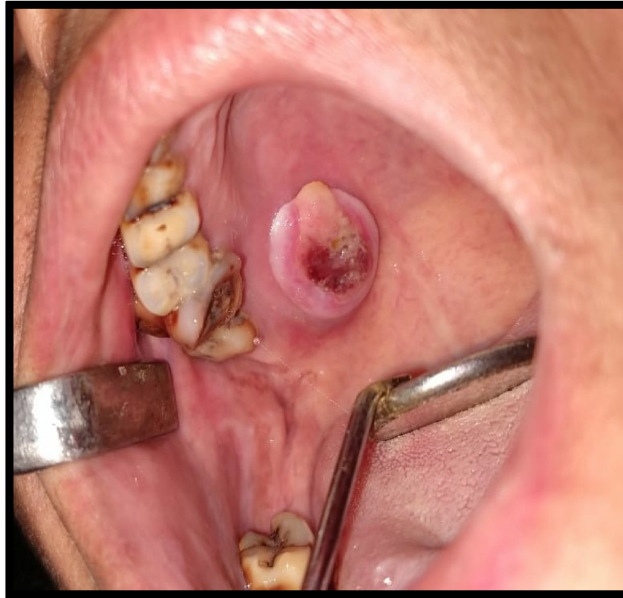

Figure1: A diffuse swelling over the right side of hard and soft palate.

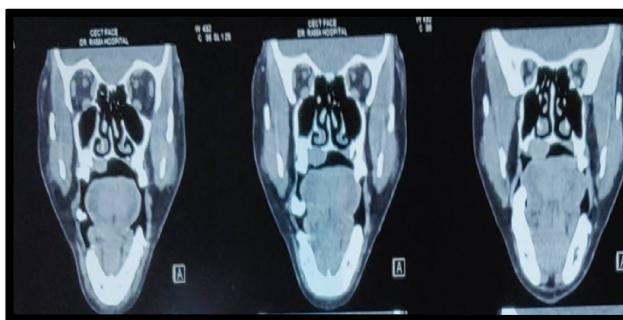
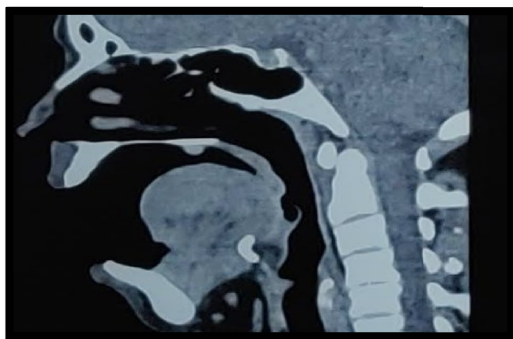

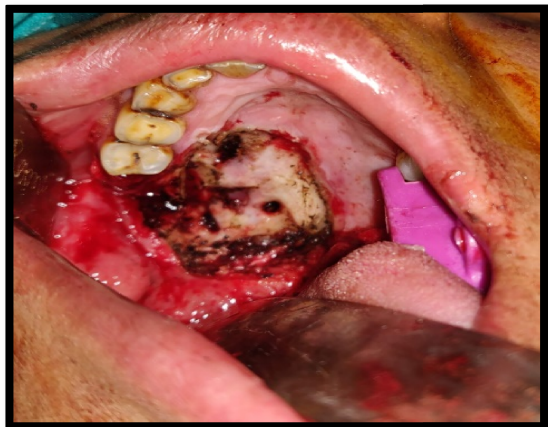
Figure 2: Computed Tomography Shows Extension of lesion with bony Erosion to palate.

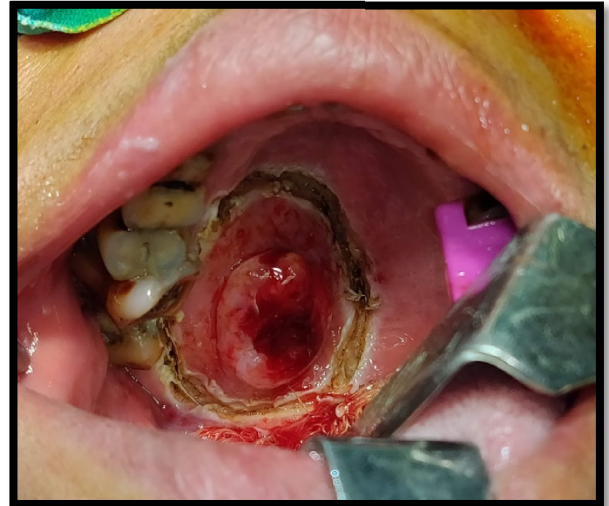

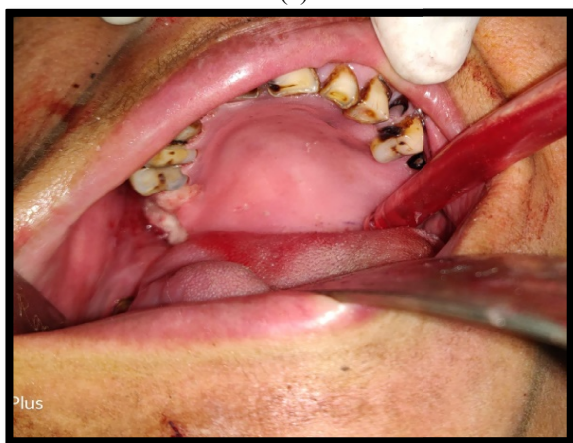
Figure 3: Marking of lesion for Wide Excision, avoiding excess involvement of Palatal mucosa.

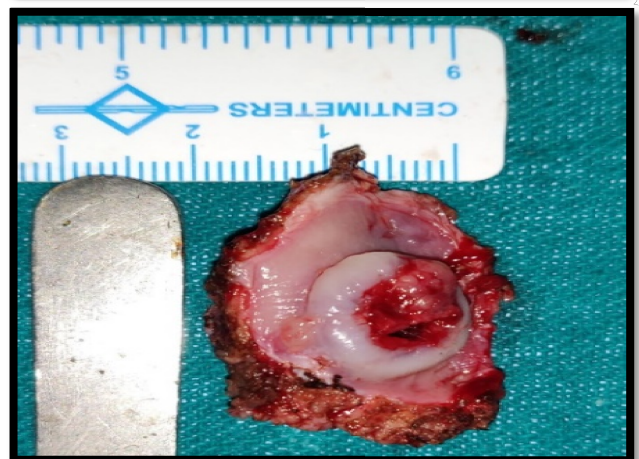
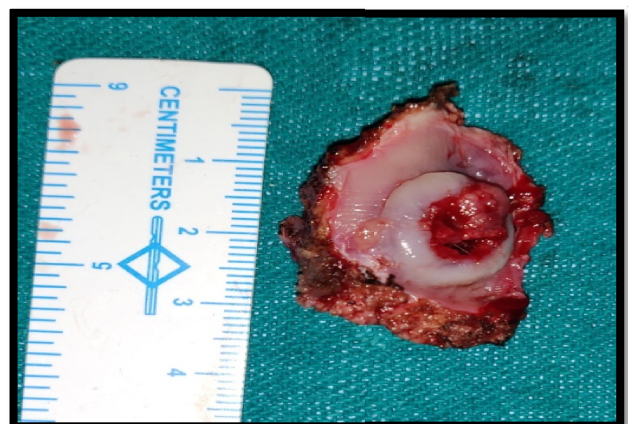
Figure 4: Wide Excision has done shows tissue size of approximately 3.8cm x 2cm.



(a)



(b)

Figure 5: (a). Soft tissue defect created after Wide Excision of Lesion, Greater Palatine Foramen is Clearly appreciated with bony breach

(b). Palatal Obturator is prepared to cover the soft tissue defect, prior to insertion of Obturator COE PACK is placed so avoid any irritation to bone.

Discussion

Histologically, it is highly variable in appearance. Classically it is biphasic and is characterized by a mixture of polygonal epithelial and spindle-shaped my epithelial elements in a variable background stroma that may be mucoid, myxoid, and cartilaginous or hyaline [4, 7]. Epithelial elements may be arranged in duct-like structures, sheets, clumps or interlacing strands and consists of polygonal, spindle or stellate-shaped cells. Areas of squamous metaplasia and epithelial pearls may occur [3]. The tumor is not enveloped, but is surrounded by a fibrous pseudo capsule of varying thickness. The tumor extends through normal glandular parenchyma

in the form of finger-like pseudopodia, but this is not a sign of malignant transformation [2, 5].

Each tumor shares with others the essential feature of being composed of both epithelial and mesenchymal-like tissues. The proportion of each of these elements varies widely and one or the other is often predominant. The “cellular” type of pleomorphic adenoma is one in which the epithelial element predominates, whereas the “myxoid” type is composed mostly of a xomatous or my chondromatous mesenchymal -like element. The “mixed” type is a classic form. Distinctive epithelial cell types include spindle, clear, squamous, basaloid, cuboidal, plasmacytoid, oncocytic, mucous and sebaceous [7].

The diagnosis of pleomorphic adenoma is established on the basis of history, physical examination, cytology and histopathology. An incision biopsy must be performed to determine the proper management regimen and treatment. Computed tomography scan and MRI can provide information on the location and size of the tumor and extension to surrounding superficial and deep structures. Fine-needle aspiration cytology and incisional biopsy can aid in the diagnosis [2,6,9].

The treatment is strictly wide local excision with the removal of periosteum or bone if they are involved.

The differential diagnosis for this case includes palatal abscesses, odontogenic and non-odontogenic cysts, soft tissue tumors such as fibroma, lipoma, neurofibroma, neurilemmoma, and lymphoma as well as other salivary gland tumors [10].

Palatal abscess could be ruled out by clinical examination since the source of a palatal abscess, which is typically a non vital tooth in the vicinity or a localized periodontal defect, was not found. Both odontogenic and non-odontogenic cysts could be ruled out at the time of exploration into the mass since it did not demonstrate a cystic nature. Palatal tissues contain components of soft tissue and harbor minor salivary gland tissues. My epithelium is a benign epithelial salivary gland tumor, having plasmacytoid or spindled my epithelial cells [10].

Differentiation between benign and malignant tumors is not possible without histopathology. Nucleation of pleomorphic adenomas leads to a high recurrence rate, so it should be avoided. Classically it has two phases and is characterized by both spindle-shaped my epithelial elements and polygonal epithelial cells in different background stroma which could be mucoid, myxoid, cartilaginous or hyaline. Epithelial elements are arranged in the form of sheet, duct-like structures and spindle shape cells. In “cellular” type of pleomorphic adenoma the epithelial element is

dominant and “my xoid” type possess my xomatous element. The classic form is a mixed type. Different epithelial cell types are spindle, clear, squamous, basaloid, cuboidal, plasmacytoid, oncocytic, mucous and sebaceous [10,11].

Whole of the tumor is enveloped in a pseudo capsule. The tumor gives off finger-like projections called as pseudopodia through normal glandular parenchyma. Management is by complete wide surgical excision of tumor besides the whole involved periosteum [10, 11].

Conclusion

- Mostly tumors of salivary gland must be incised because of the probability of transformation into malignancy.
- Adequate strategy for the treatment of pleomorphic adenomas is wide excision with negative margins because of absence of encapsulation, merging into normal tissue. As chances of recurrence will reduce with wide surgical excision technique.
- A biopsy of the excised specimen should be sent for histopathological examination to support the diagnosis.

References

- [1] Luna MA, Batsakis JG, El-Naggar AK (1991) Salivary gland tumors in children. *Ann OtolRhinolLaryngol* 100:869–871
- [2] Jorge J, Pires FR, Alves FA, Perez DEC, Kowalski LP, Lopes MA (2002) Juvenile intraoral pleomorphic adenoma: report of five cases and review of the literature. *Int J Oral MaxillofacSurg* 31:273–275
- [3] Sanjay Byakodi, ShivayogiCharanthimath, SantoshHiremath 4, Kashalikar JJ (2011) Pleomorphic adenoma of palate: a case report. *Int J Dent Case Reports* 1:36–40
- [4] Mubeen K, Vijayalakshmi KR, Patil AR, Giraddi GB, Singh C (2011) Benign pleomorphic adenoma of minor salivary gland of palate. *J Dent Oral Hyg* 3:82–88
- [5] Batsakis JG (1981) Neoplasms of the minor and ‘lesser’ major salivary glands. In: *Tumors of the head and neck*. The Williams and Wilkins Company, Baltimore, p 38–47
- [6] Suen JY, Synderman NL (1993) benign neoplasms of the salivary glands. In: Cummings CW, Fredrickson JM, Harker LA, Krause CJ, Schuller DE (eds) *Otolaryngology—head and neck surgery*. Mosby Year Book, St. Louis, pp 1029–1042
- [7] Dhanuthai K, Sappayatosok K, Kongin K (2009) Pleomorphic adenoma of the palate in a child: a case report. *Med Oral Patol Oral CirBucal* 14:E73–E75
- [8] Moubayed SP, AlSaab F, Daniel SJ (2010) rapidly progressing palatal pleomorphic adenoma in an adolescent. *Int J PediatrOtorhinolaryngol Extra* 5:141–143
- [9] Yamamoto H, Fukumoto M, Yamaguchi F, Sakata K, Oikawa T (1986) Pleomorphic adenoma of the buccal gland in a child. *Int J Oral MaxillofacSurg* 15:474–477
- [10] Byars LT, Ackerman LV, Peacock E (1957) Tumors of salivary gland origin in children: a clinical pathologic appraisal of 24 cases. *Ann Surg* 146:40–51
- [11] Lopez-Cedrun JL, Gonzalez-Landa G, Birichinaga B (1996) Pleomorphic adenoma of the palate in children: report of a case. *Int J Oral MaxillofacSurg* 25(3):206–207
- [12] Shaaban H, Bruce J, Davenport PJ (2001) Recurrent pleomorphic adenoma of the palate in a child. *Br J PlastSurg* 54:245–247
- [13] Feinmesser R, Gay I (1983) Pleomorphic adenoma of the hard palate: an invasive tumour *J LaryngolOtol* 97:1169–1171
- [14] Clauser L, Mandrioli S, Dallera V, Sarti E, Galie` M, Cavazzini L (2004) Pleomorphic adenoma of the palate. *J CraniofacSurg* 15:1026–1029
- [15] Pogrel MA (1994) The management of salivary gland tumors of the palate. *J Oral MaxillofacSurg* 52:454
- [16] Noghreya A, Gatot A, Maor E et al (1995) Palatal pleomorphic adenoma in a child. *J LaryngolOtol* 109:343
- [17] Weber AL (1981) Pleomorphic adenoma of the hard palate. *Ann OtolRhinolLaryngol* 90:192–194
- [18] De Courten A, Lombardi T, Samson J (1996) Pleomorphic adenoma in a child: 9-year follow-up. *Int J Oral MaxillofacSurg* 25:293–295
- [19] Lopez-Cedrun JL, Gonzalez-Landa G, Birichinaga B (1996) Pleomorphic adenoma of the palate in children: report of a case. *Int J Oral MaxillofacSurg* 25:206

To cite this article: Pleomorphic Adenoma of Hard Palate: A Case Report and Review of Literature, Shivendra Kumar Singh, Waseem Khan, Nishant Singh, Mayank Verma, Rama Univ. J. Dent. Sci. 2018 September; 5(3): 15-18.